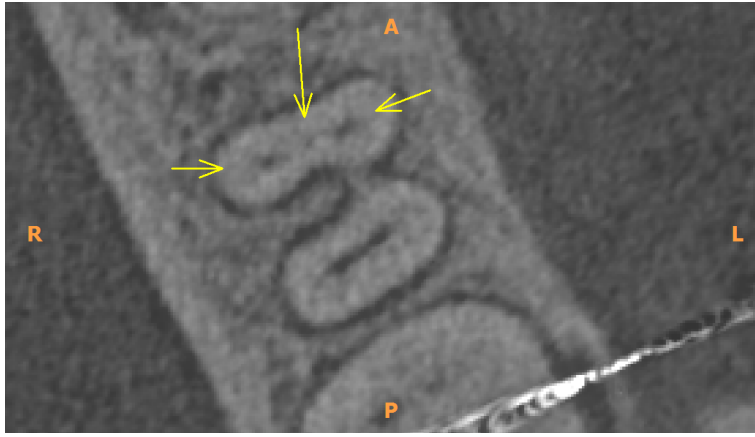
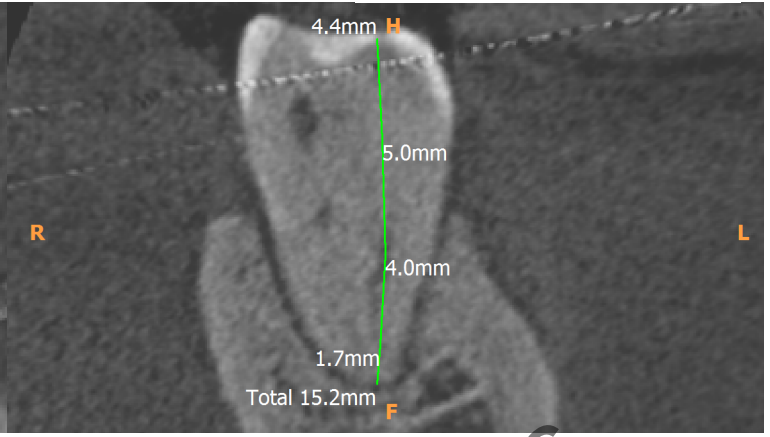


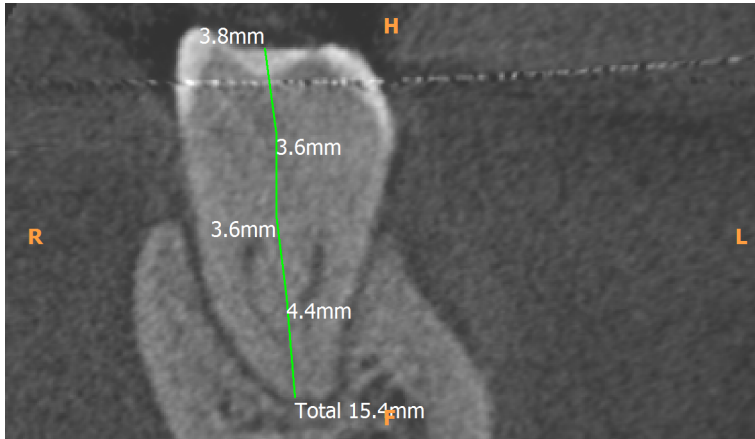
# Radon Maxillofacial Diagnostics




Mesial root i.r.t 37 showing 3 canal spaces



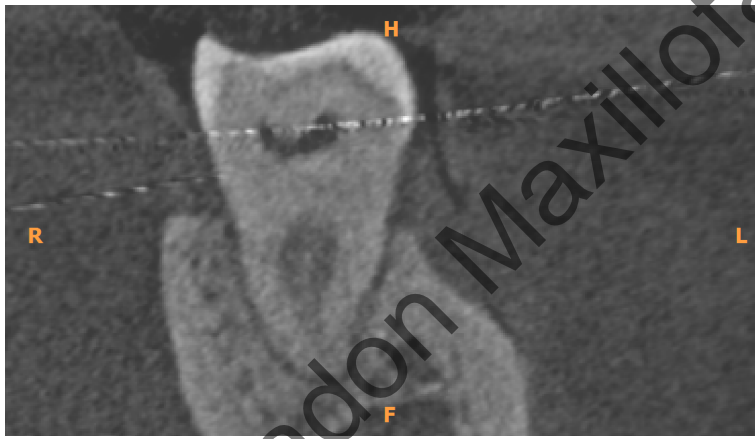Mesiobuccal canal space (M1)



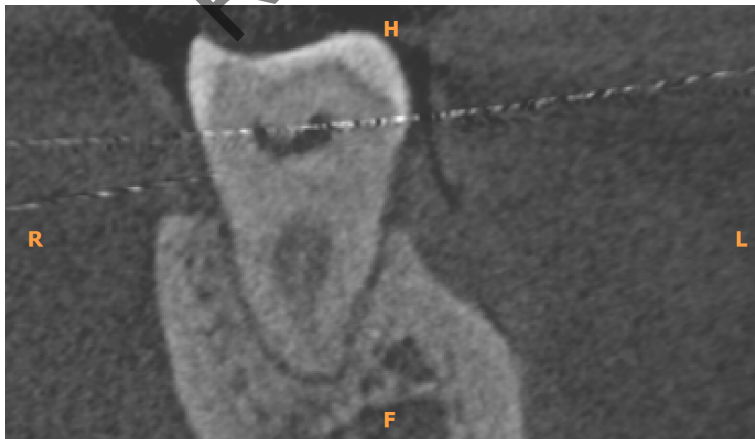
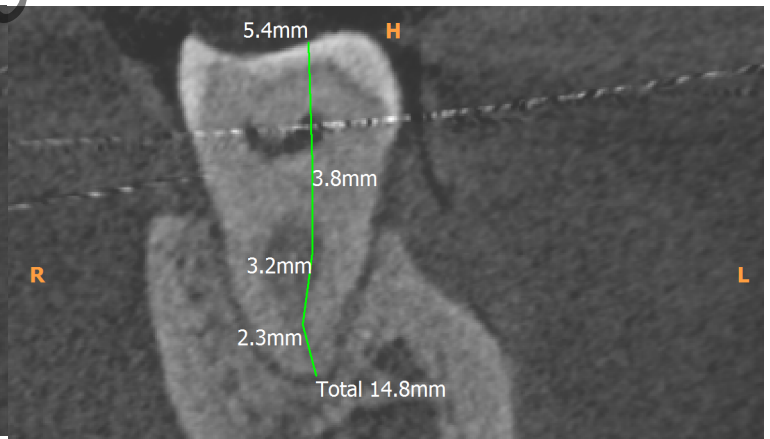
Middle mesial canal space (M2)



Mesiolingual canal space (M3)



Distobuccal root canal space i.r.t 37



Distolingual root canal space i.r.t 37

